

sune  
KOS

Cell 15

The new era  
of cellulite  
treatment

DESIGNED to  
RECREATE

HYGAA  
+BC

NO LOOKALIKES

PLAAT  
FORM





Cell 15

WHAT'S NEW  
ABOUT  
CELLULITE?

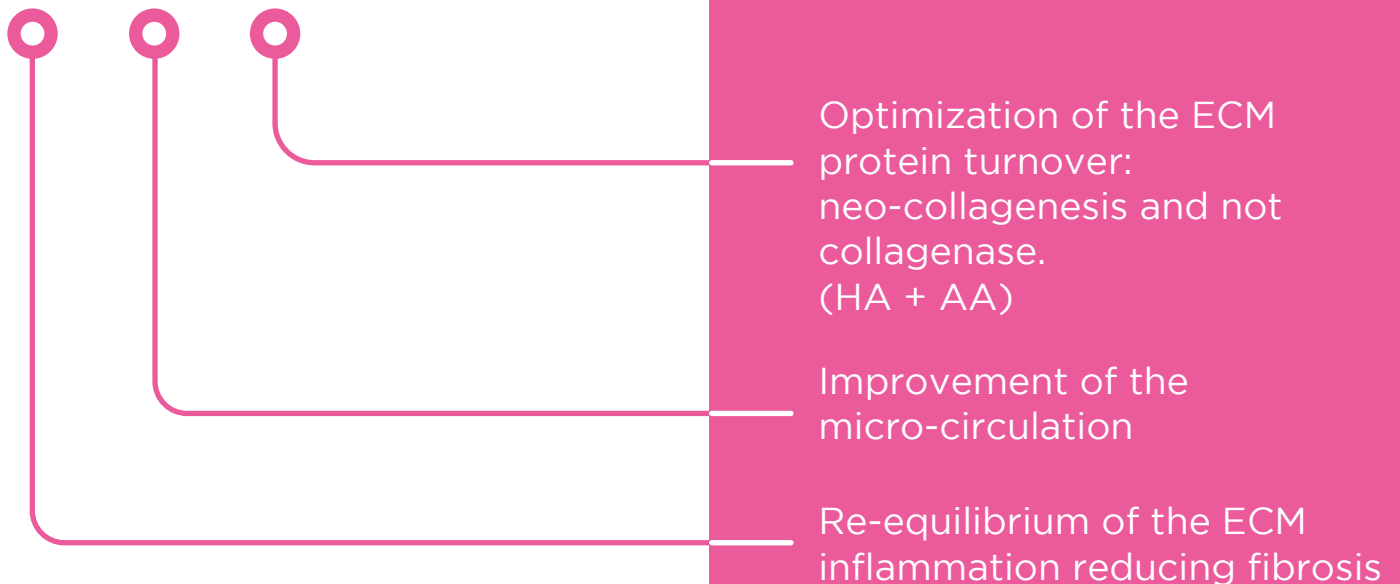
In the evolutionary phases of cellulite, clinically called “Edematous Fibrosclerotic Panniculopathy” (EFP) the intradermal therapy was mainly addressed to the treatment of edema and microcirculation.

**Today, numerous pathophysiological considerations demonstrate the need to intervene also and especially on the Extra Cellular Matrix (ECM).**



The synergy of the mix of HA+AA and an Alkaline Solution determines the physiological induction of the precise mechanisms to improve the structure of the ECM, adjusting micro circulation and reducing fibrosis.

Sunekos Cell acts:



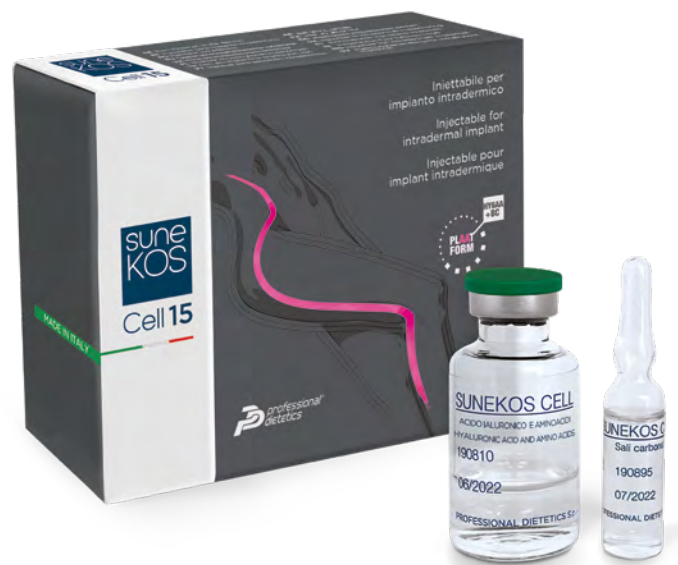**This new approach is designed to restore the homeostasis of the skin and adipose tissue thanks to a non-lipoclastic or lipolytic method.**

**REBUILDING  
rather than  
DESTROYING**




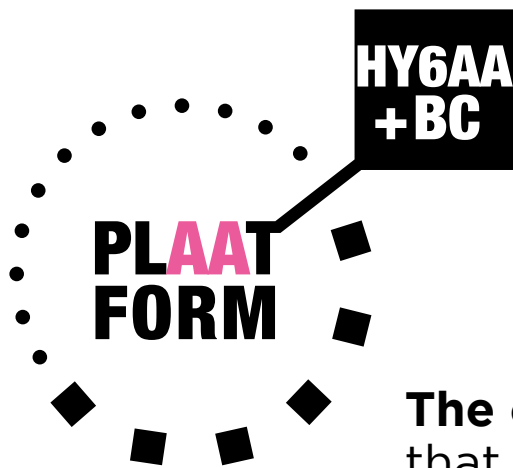
Cell 15

THE  
PRODUCT



Reconstituted  
as 15 ml





**The one and only formula**  
that counteracts acidosis  
and restructures the extracellular matrix.

**For a successful, non-invasive treatment of cellulite.**

---

**Low molecular weight hyaluronic acid (HA) 200 kD**  
Targeted stimulating action on fibroblasts, through binding with specific receptors for HA fragments

**Amino Acids (AA)**  
Optimal neo-synthesis of collagen and elastin

**Carbonate and Bicarbonate salts**  
For the neutralisation of typical acidosis in latent inflammation that characterizes both the early and late stages of the cellulite



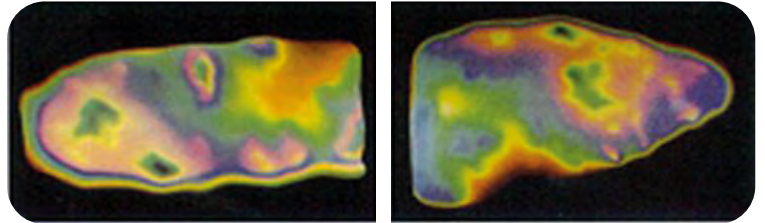
Cell 15

# STAGES OF CELLULITE

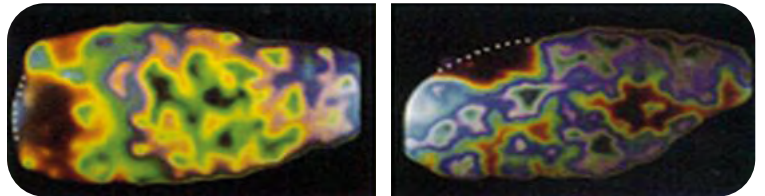
## STAGES I AND II OF CELLULITE

---

Stage 1



Stage 2

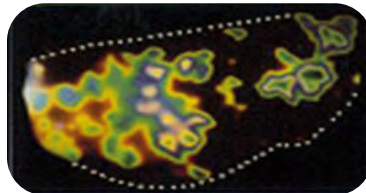


[2]

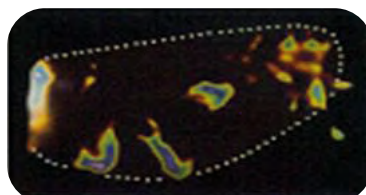
## STAGES III AND IV OF CELLULITE

---

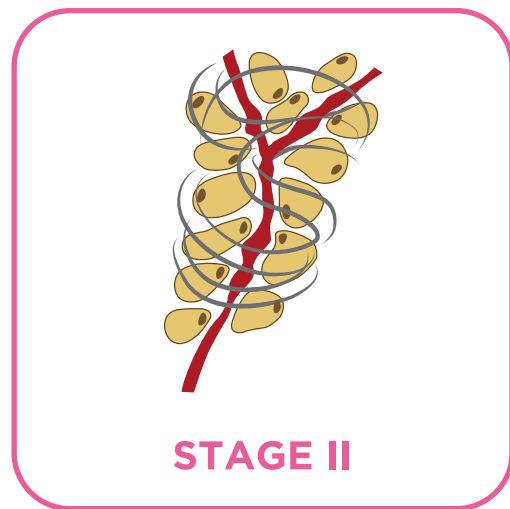
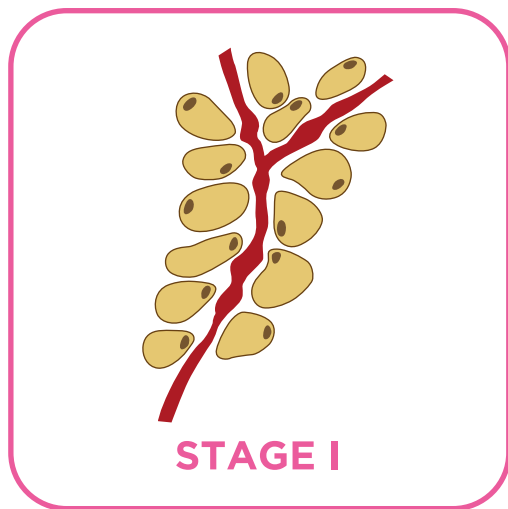
Stage 3



Stage 4

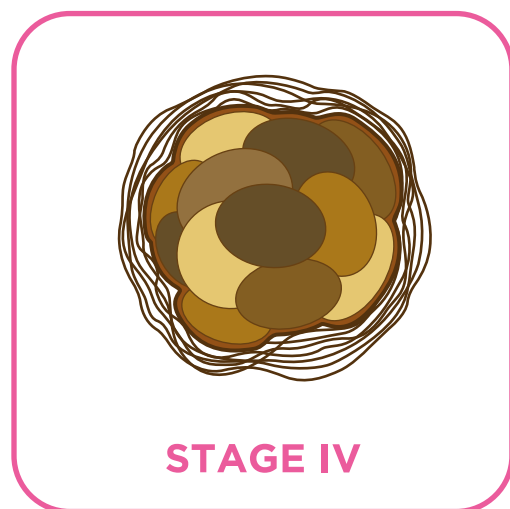
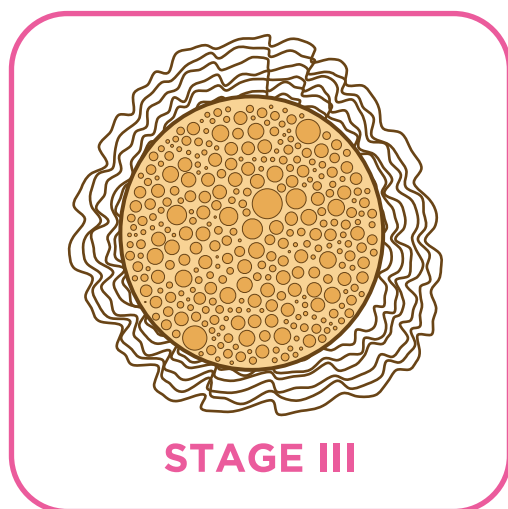


[2]



Stages I and II of cellulite presents an edemato - inflammatory condition of the tissue associated with hypo-oxygenation and acidosis.

Stages I and II can be treated with ATL-n Technique (Across Tension Lines needle).



The pathogenetic mechanism of late stage of cellulite is mostly related to the aging phenomena of tissues (inflamm-aging / acidosis) already degenerated in fibrosis and subsequently in sclerosis. This condition is often related to menopause when the decrease of the **hormones** is worsening the process.

Stages III and IV can be treated with Cannula and ATL-c Technique (Across Tension Lines cannula).



Cell 15

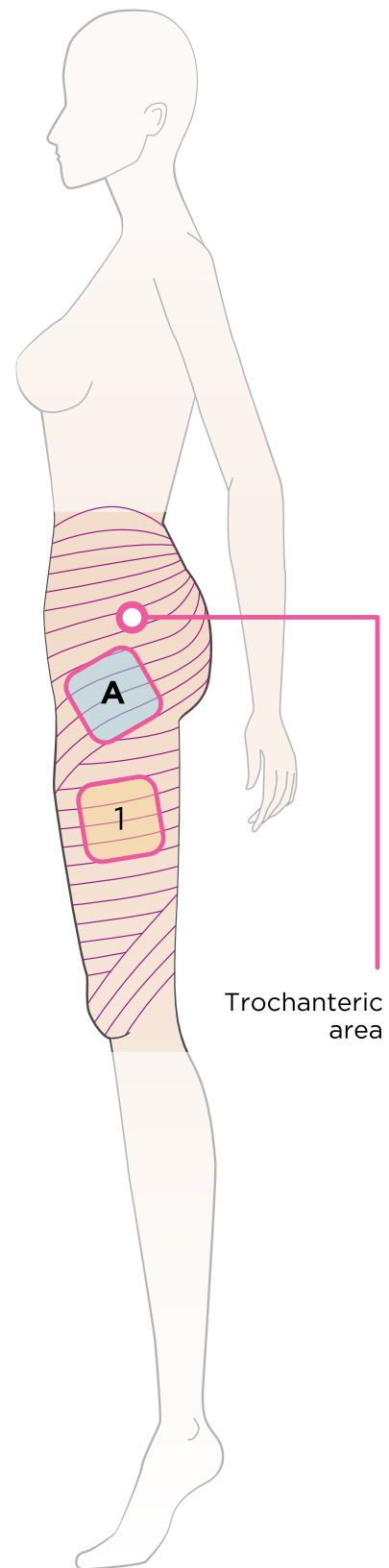
## FOLDING LINES IN CELLULITE TREATMENT

According to studies on the “folding lines”<sup>[1]</sup>, the injection rationale is to follow ideal orthogonal lines on the natural folding ones

### INJECTION SCHEME:

3 Areas per side

(2.5 ml per Area → 7.5 ml per leg).

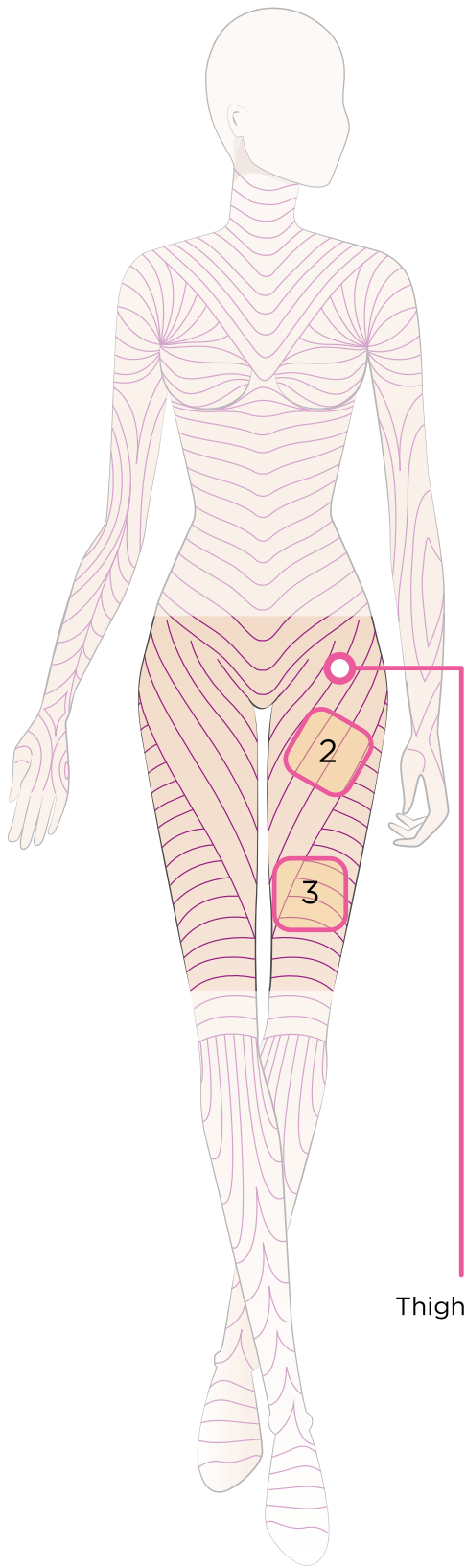


Always inject Area

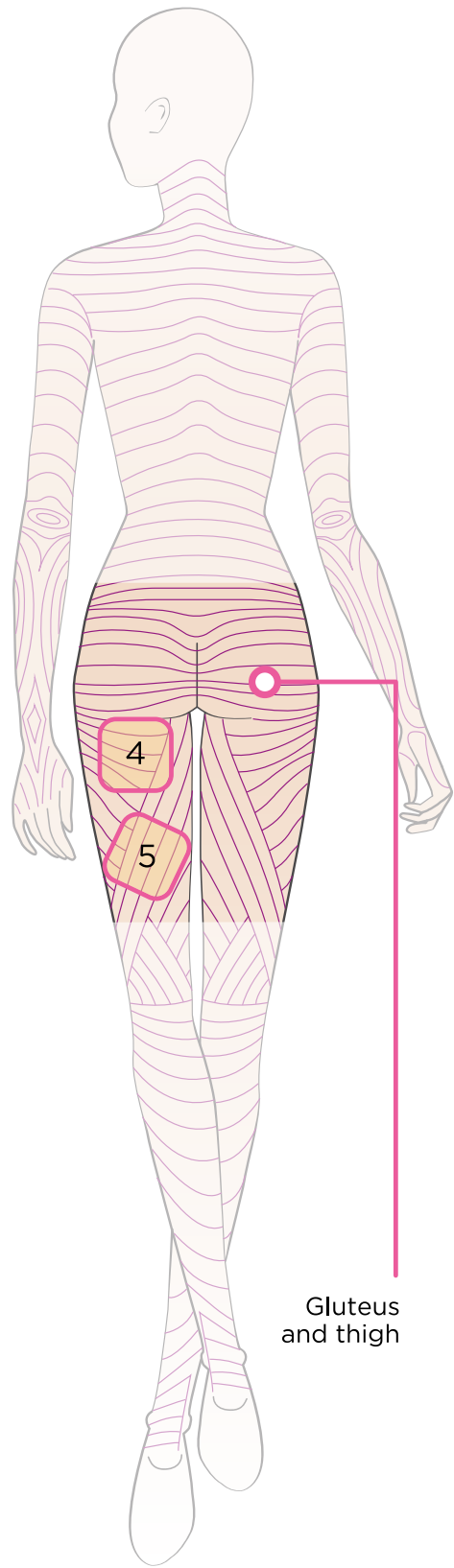
**A**

in combination with





Thigh



Gluteus and thigh

2.5 ml per Area

two other areas choosing between Area

1

or

2

or

3

or


4

or

5

looking at the needs of the patient.

# STAGES I AND II OF CELLULITE

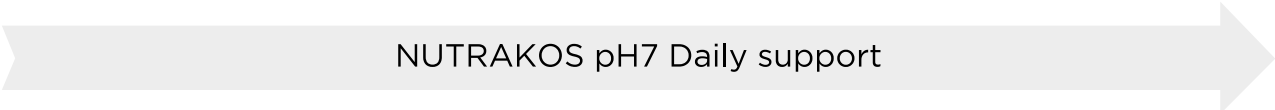
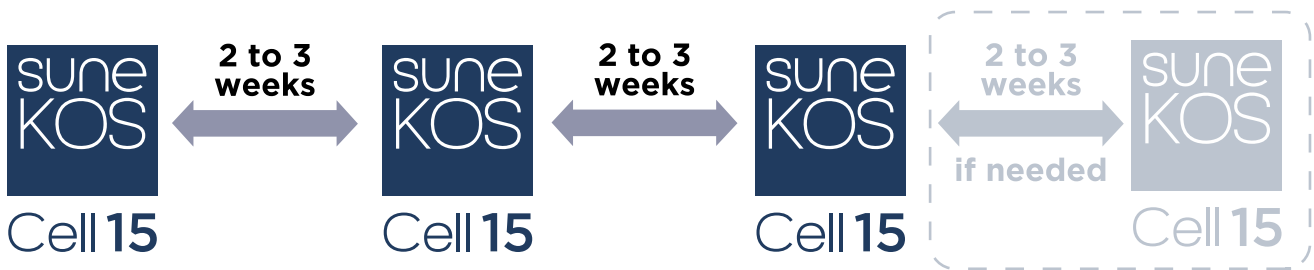


The diagram shows a thigh with purple horizontal lines representing tension lines. A 12x12 cm grid of dashed lines indicates treatment points. Below the grid, a needle is shown at a 30-degree angle, with a label 'Medium/Deep Dermis' pointing to the needle tip.

- Needle 12mm, 30G
- Needle inclination 30°
- Medium Deep Dermis
- 0.15 ml per point
- Perpendicularly to Folding Lines



## Cell 15

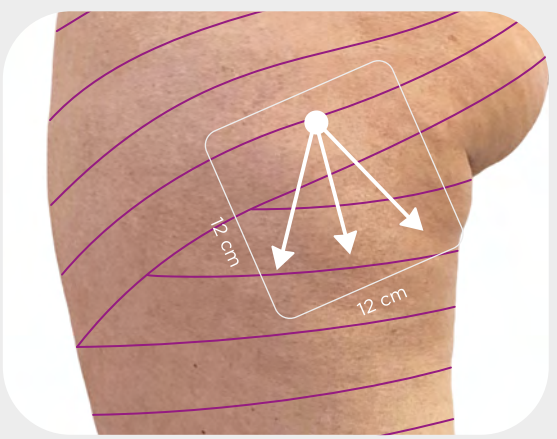


**Maintenance**  
1 or 2 sessions  
after 4 or 6 months

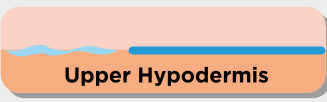
**Repeat the**  
full cycle  
every 12 months



# STAGES III AND IV OF CELLULITE



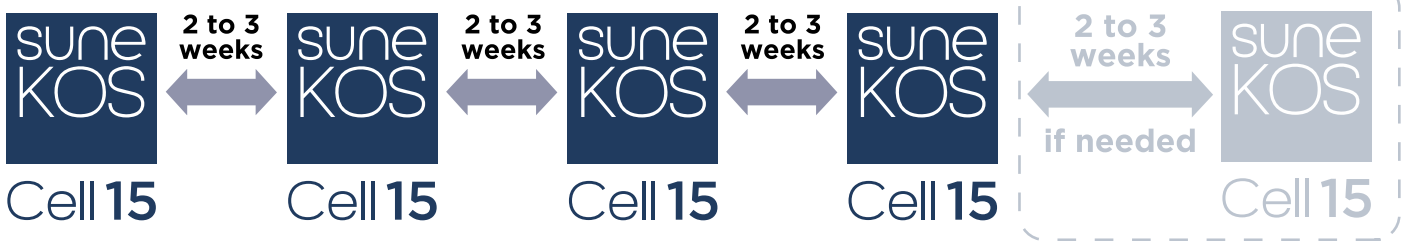
- Cannula 27G and 40-50 mm or 22G and 50-70mm
- Deep Dermis Injection
- Fan Technique
- 0.8 ml per injection
- ATL-c Technique Cannula



Upper Hypodermis



## Cell 15

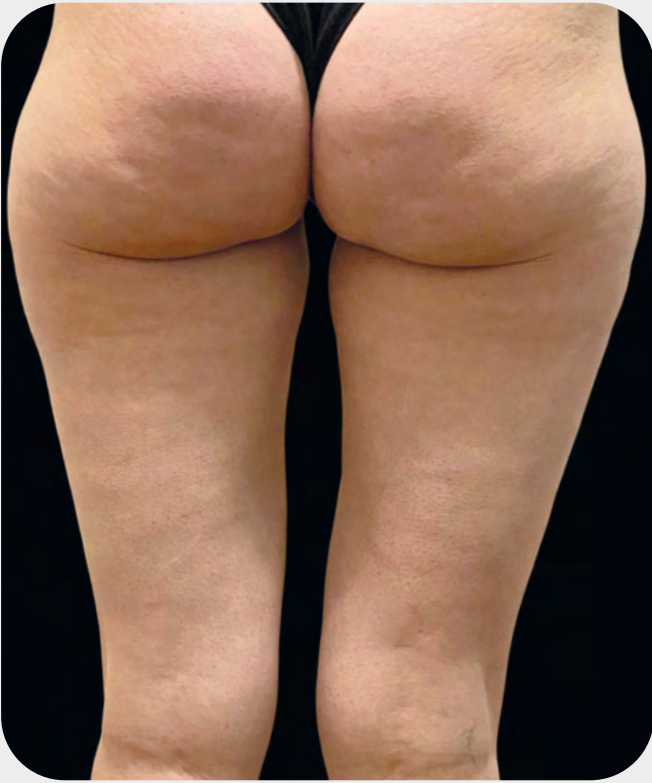

NUTRAKOS pH7 Daily support

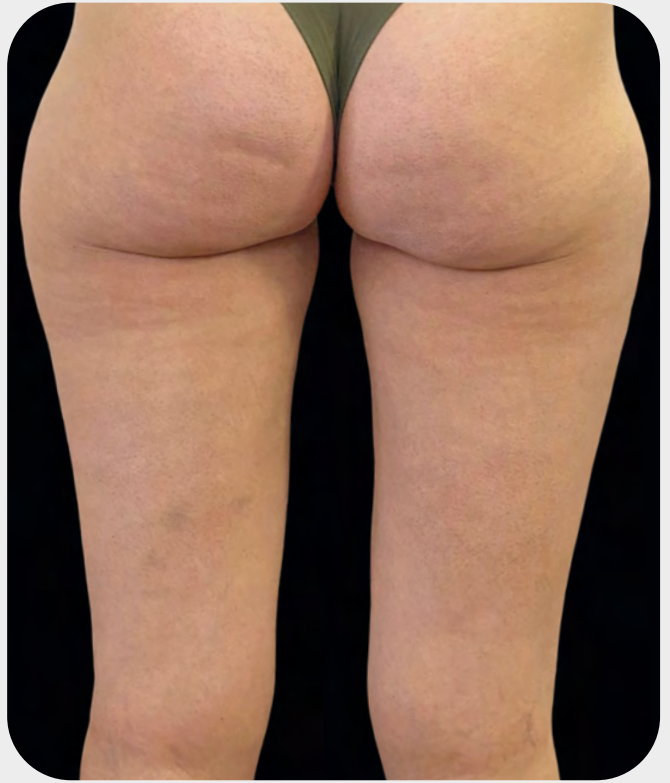Maintenance  
1 or 2 sessions  
after 4 or 6 months

Repeat the  
full cycle  
every 12 months

BEFORE

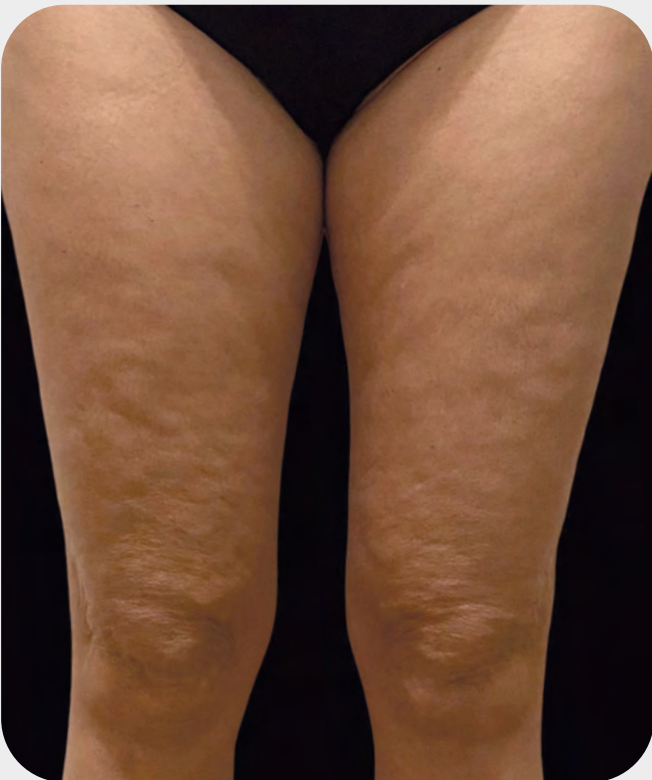

AFTER

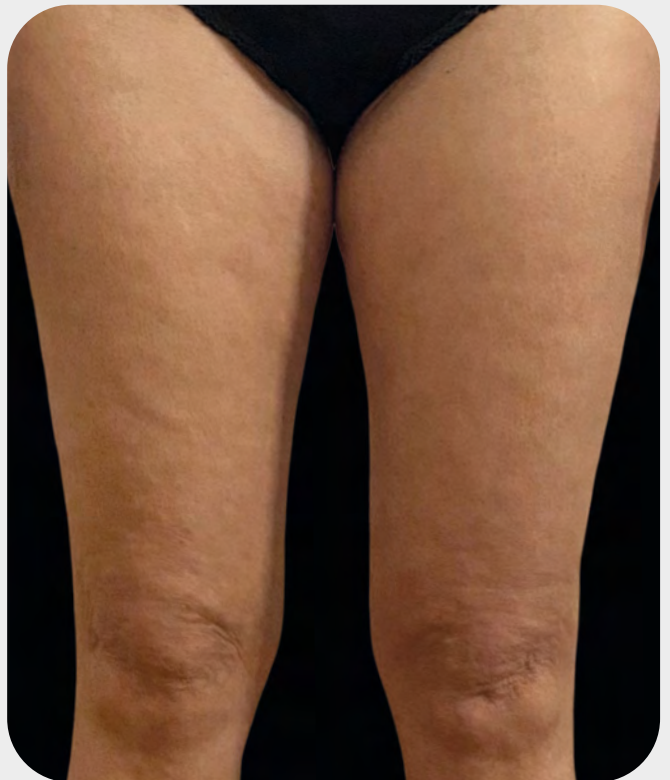

Courtesy by Elena Fasola MD

BEFORE



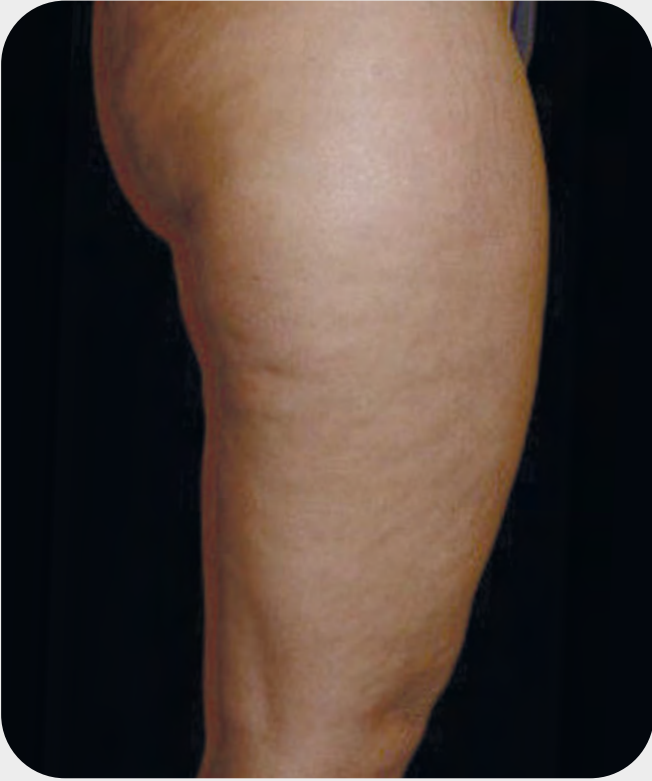AFTER



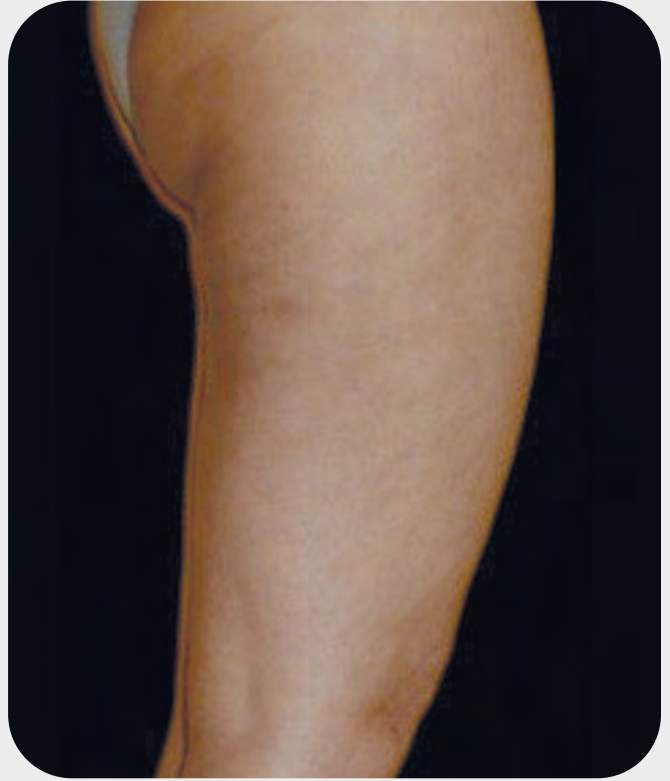Courtesy by Elena Fasola MD



BEFORE

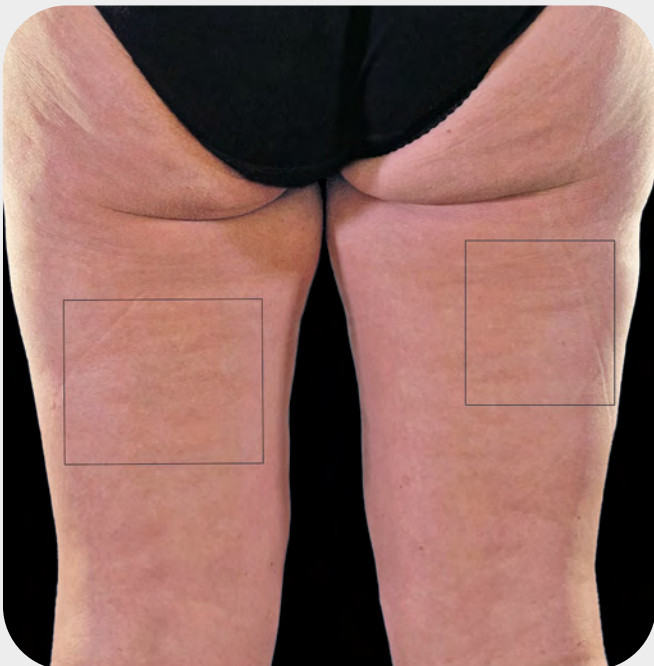

AFTER

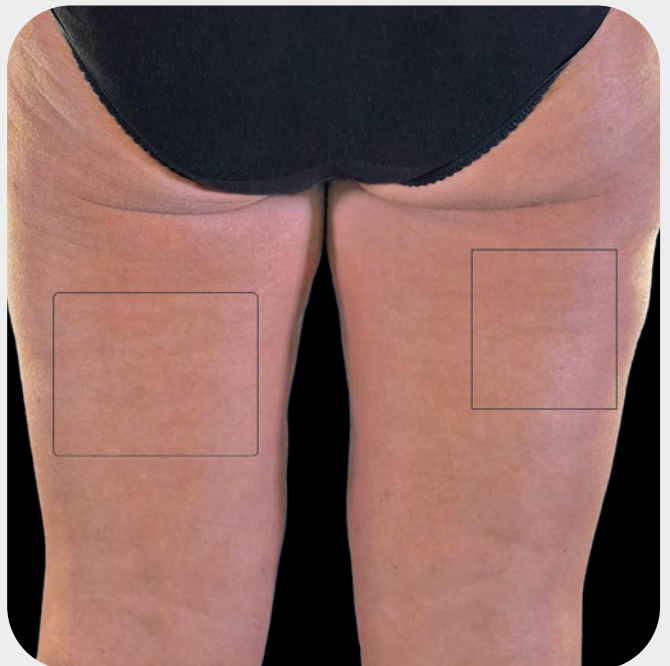

Courtesy by Elena Fasola MD

BEFORE



AFTER



Courtesy by Mark Holmes MD



# STAGES III AND IV OF CELLULITE



Cell 15

CLINICAL  
EVALUATION

Preliminary study on 25 healthy subjects with different stages of cellulite, divided into 2 groups, undergoing Sunekos Cell treatment.<sup>[2]</sup>

## **Group A**

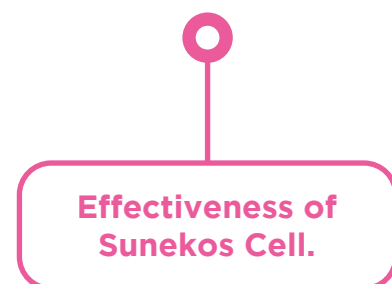11 subjects with stages I and II cellulite

## **Group B**

14 subjects with stages III and IV cellulite

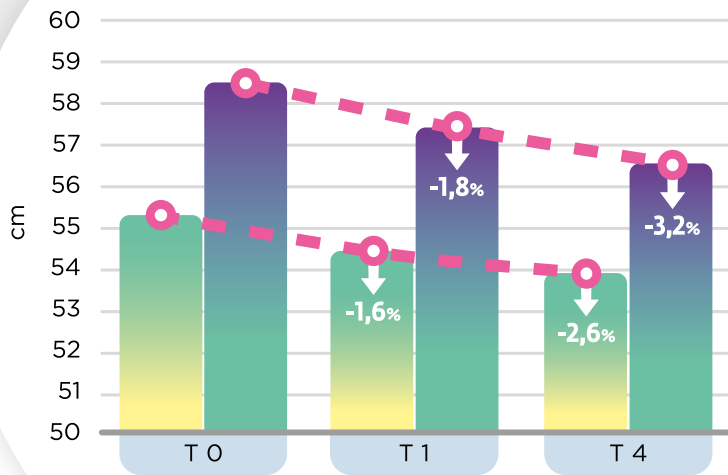
*Clinical, morphometric and ultrasound evaluation at baseline, 1 month and 4 months after the treatment*

## CONCLUSIONS



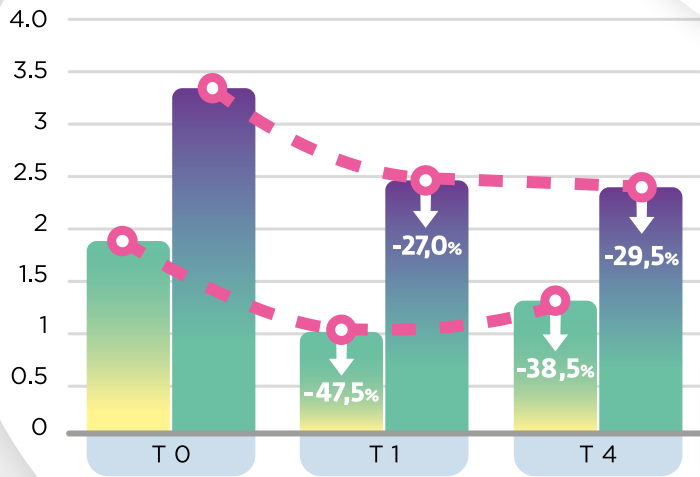
Effectiveness of  
Sunekos Cell.

## CIRCUMFERENCES



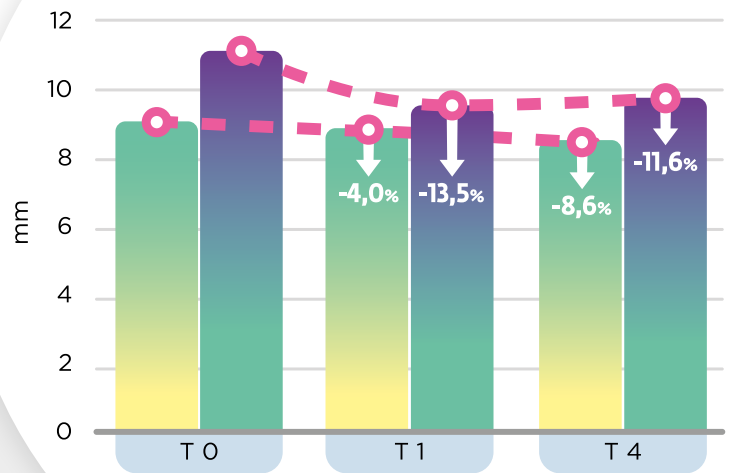
GROUP A GROUP B

## VISUAL ASPECT GRADE



GROUP A GROUP B

## ULTRASOUND

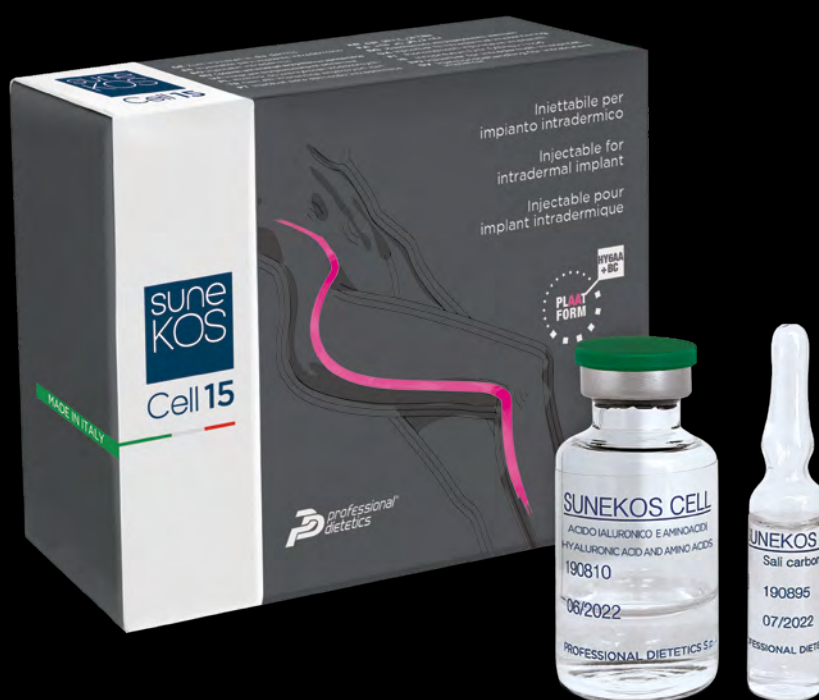

GROUP A GROUP B

## RESULTS\*

Clinical evaluation score is reduced in both groups also thanks to the injective technique adapted to the severity of the disease.

Maintenance of results after 4 months.



## Sunekos Cell 15

CE 0373

Registered as  
CE Medical Device Class III

One pack of Sunekos Cell 15  
contains 1 treatment (15 ml)  
**to be reconstituted**

-1x vial Carbonate/Bicarbonato  
-1x bottle low molecular weight (200kD)  
Sodium Hyaluronate/Amino Acids (HA/AA)

### Bibliography


- [1] Lemperle G. et al. The Direction of optimal skin incisions Derived from Striae Distensae - Plast. Reconstr. Surg. 2014 Dec;134(6):1424-1434.  
[2] A. Sparavigna, Injective treatment of the so-called cellulite: a new approach aimed at restructuring extracellular matrix of deeper layers of the skin. Efficacy and safety of a new specific formula (part 1 & 2) - JPD Vol 18 n2 2022

esthetic med  
arzt- und spitalbedarf

esthetic med GmbH  
Chli Ebnet 3 - 6403 Küssnacht am Rigi - Switzerland  
Tel: +41 44 802 33 88 - Email: info@estheticmed.ch  
www.estheticmed.ch

 professional  
dietetics

Via Ciro Menotti, 1/A - 20129 - Milan - Italy  
Tel: +39 02 744020  
www.professionaldietetics.com  
Email: info@pd-international.com

 @sunekos